



Prof. Dr. Dr. José Luis Calvo Guirado

DDS, PhD, Eu PhD, MS.

Full Professor of Oral Surgery and Implant Dentistry. Faculty of Health Sciences. San Antonio Catholic University of Murcia (UCAM).

Doctor in Dentistry and in Bioengineering and Biomaterials.

Director of the International Chair of Research in Dentistry (UCAM).

Murcia, Spain

NEW PROCEDURE TO PROCESS EXTRACTED TEETH AS GRAFT IN ALVEOLAR RIDGE POST-EXTRACTION

Experimental study in dogs

SUMMARY

The objective of this investigation was to evaluate the efficiency and new bone formation derived from freshly crushed extracted teeth (particulated teeth), that are grafted immediately in the post-extraction sites, in comparison with sites without graft filling observed over 90 days in experimental animals.

Six Beagle dogs were used. The bilateral premolars P2, P3, P4 and the first mandibular molar were extracted atraumatically. The clean and dry teeth were ground immediately using the Smart Dentin Grinder, a specially designed apparatus for this type of procedure. The tooth particles obtained were 300-1200 μm , which were subsequently sieved through a special sorting filter into two compartments. The crushed teeth were grafted into small and large alveolar ridge post-extraction.

The animals were divided at random into two experimental groups: Group A «Dentin Grinder» and Group B «Control». This study evaluated tissue healing and bone formation by histological and histomorphometric analysis at 60 and 90 days.

The bone formation around the crushed tooth was evaluated. A greater bone formation was observed in Group A compared to the Control Group at 60 days ($p < 0.05$). The immature bone was lower in the Dentin Grinder Group (22.9%) compared to the Control Group (54.7%). There were significant differences between bone formation at 90 days, but the new bone formation was greater in Group A than in the Control Group. No significant differences were found in new bone formation when compared small and large alveolar ridge post-extraction sites.

Autogenous crushed tooth particulate, grafted immediately after extractions should be considered as a new biomaterial suitable for the preservation of the alveolar ridge and bone augmentation and can also be used in maxillary sinus augmentation procedures.

Keywords: Smart Dentin Grinder and sorter; Autogenous particulate dentin graft; Socket preservation.

INTRODUCTION

Many biomaterials have been used in dental surgery and a variety of new biomaterials have been marketed for maxillofacial surgery, periodontal procedures, implant surgery and other fields. Graft biomaterials are used to repair hard and soft tissue defects. Synthetic bone is relatively inexpensive and does not hold risk of disease transmission, but lacks the ability to promote osteogenesis and osteoinduction and, therefore, its usefulness is limited as for the formation of viable bone.

Extraction is one of the most widely performed procedures in dentistry where the tooth is still considered a clinical waste and, therefore, are discarded (1).

The human demineralized dentin matrix, created from extracted human teeth, was developed in 2008 and has been evaluated for its osteoinductive, osteoconductive and remodeling capacity in implant dentistry. Dentin and bone are composed of: collagen (30%), hydroxyapatite (60%) and body fluid (10%) by weight (2-4).

Dentin is an acellular matrix rich in collagen without vessels, while bone is a cellular tissue with vessels. The chemical composition of teeth, especially dentin and bones, are very similar. Enamel consists of 96% inorganic substances and 4% water, while dentin has 65% inorganic substances, 35% organic substances

and water. Cementum is composed of 45-50% of inorganic substances, 50-55% of organic substances and water. Finally, the alveolar bone has 65% inorganic substances and 35% organic substances (5).

Bone and dentin consist of liquid (10%), collagen (20%) and hydroxyapatite (70%) by volume. These are the categories in which we typically evaluate biomaterials consisting of collagen and ceramic materials (6-9).

Base on that, we have assumed that non-functional teeth are an ideal native resource to be

grafted immediately or even deferred as shown by the South Korea Tooth Bank.

Several studies have shown that the properties of the crushed tooth could act as a bone substitute induced by dentin and dentin pulp, looking at recycling of human teeth as a new graft material for bone regeneration in Japan and Korea (5, 10). Nowadays, various bone graft materials are being created thanks to development of advanced bioactive materials technologies. As a result, alveolar surgery can handle repair of bone defects with various methods in implant placement, periodontal surgery, and maxillofacial surgery.

Kim and his team carried out research on the development of biomaterials using human teeth since 1993, and recently reported on the results of several of our advanced studies (11-32).

Other authors obtained a Korean and American patent based on this investigation of crushed teeth to develop bone grafting materials using animal teeth (33-34). Still, the new autogenous bone graft is still considered the gold standard, since it exhibits properties of instructive matrix of bioactive cells and is non-immunogenic and non-pathogenic, despite the need to harvest bone and the possible morbidity resulting in a secondary site.

A human dentin autograft was reported in 2003 as a first clinical case (35), while the human bone autograft was made in 1820. A long period of time elapsed between dentin and bone autografts. In 2009,

Korea Tooth Bank was established in Seoul for the processing of tooth-derived materials, initiating an innovative medical service for bone regeneration. The results of the Korean study suggests that the graft material of autogenous teeth is a viable option for augmentation of alveolar bone after oral surgery (36). However, the procedure takes a long time, since the graft is ready after many hours and days of water extraction.

A "Smart Dentin Grinder TM" apparatus was designed to crush and sort extracted teeth into dentin particles of specific size. A chemical

“BONE GRAFT MATERIALS ARE BEING CREATED DUE TO ADVANCEMENTS IN BIOACTIVE MATERIAL TECHNOLOGY

cleanser was applied to eliminate bacteria for 15-20 minutes. Its novel procedure is indicated for all tooth extractions. Endodontically treated teeth are counter-indicated due to contamination of foreign materials.

The objective of this study was the histological and histomorphometric evaluation of the formation of vital bone (VB) after the filling of the tooth graft compared to the empty sockets in an animal model after 90 days of follow-up.

MATERIAL AND METHODS

The study consisted of six Beagle dogs about one year old, weighing 14-15 kg each. The Ethics Committee for Animal Research of the University of Murcia approved the study protocol that followed the guidelines established by the Directive of the Council of the European Union of February 1, 2013/53 / CEE.

The clinical examination determined that the dogs were in good general health. The animals were quarantined for the application of the rabies and vitamin vaccine. Before and after the operation, the animals were kept in cages, receiving appropriate veterinary attention with free access to water and standard laboratory nutritional support throughout the trial period. All the animals presented intact dental arches, without viral or fungal oral lesions.

The animals were pre-anesthetized with 10% zolazepam at 0.10 ml / kg and acepromazine maleate (Calmo-Neosan®, Pfizer, Madrid) 0.12-0.25 mg / kg and medetomidine 35 lg / kg (Medetor 1 mg , Virbac, CP-Pharma Handelsgesellschaft GmbH, Germany).

The mixture was injected intramuscularly into the quadriceps femoris. The animals were taken to

the operating room where, at the first opportunity, an intravenous catheter (diameter 22 or 20 G) was inserted into the cephalic vein, and Propofol infusion was administered at a rate of 0.4 mg / kg / min as a Slow constant infusion rate.

The anesthetic maintenance was performed with volatile anesthetics and the animals underwent tracheal intubation with a Magill probe for the adaptation of the anesthetic device and for the administration of volatile isoflurane diluted in oxygen (2V%). In addition, local anesthesia (Articaine 40 mg, 1% epinephrine, Normon®, Madrid, Spain) was administered at the surgical sites. These procedures were carried out under the supervision of a veterinary surgeon.

Mandibular premolars and first molars (P2, P3, P4, M1) were extracted bilaterally (Figures 1 and 2) under general anesthesia.

The teeth with multiple roots were sectioned in a buccolingual direction at the bifurcation using a tungsten carbide bur so that the roots could be extracted individually, without damaging the remaining bony walls.

The clean and dry teeth were crushed immediately after extraction using the "Smart Dentin Grinder" specially designed for this procedure. The tooth particles obtained were sized at 300-1200 um, which were sieved through a special sorting system into two compartments (Figure 3).

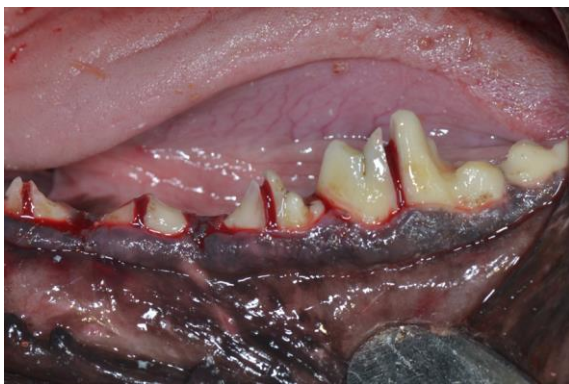

Figure 1: Premolars and mandibular molars with Odontosection.

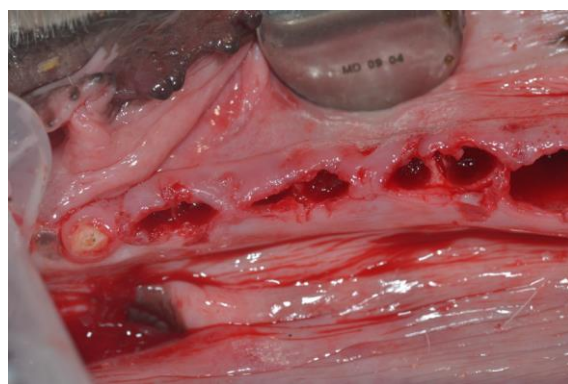


Figure 2: Alveolar ridge of premolars P2, P3 and P4 and Molars (M1).

and were allowed to heal naturally (Control Group) (Figure 5).




Figure 3a: Extraction mandibular premolars, b: Smart Dentin Grinder, c: granulometry of 300 microns post-atomized and d: granulometry of 1,200 microns post-processed.

The particulate teeth were immersed in a basic alcohol cleanser in a sterile container to dissolve all organic waste and bacteria for 15 minutes. The particles were then washed with sterile saline for 5 minutes. Then particles were dried, the small and large particles were mixed and grafted into the small and large alveolar ridge post-extraction sites.

After the extraction of alveolar ridge from P3, P4 and M1, they were filled with freshly extracted teeth (Figure 4), while the P2 post-extraction alveolar ridge on both sides remained untreated

Simple absorbable sutures (3-0 TB-15, Lorca Marin® Ref. 55346) were used so that the gums completely covered the grafted areas. The sutures were removed after two weeks.

The anterior sectors were conserved from canine to canine in order to maintain a minimal masticatory function. No intervention was performed on the maxilla. All surgery was performed under the supervision of the veterinarian assigned to the Animal Research Unit of the University.

Throughout the surgical procedure, the intravenous line was hydrated with (glucose-saline solution) (250 cm³) to aid post-surgical recovery of the animals. The following anti-inflammatory, analgesic and antimicrobial drugs were administered: anti-inflammatory Voren® (dexametasone isonicotinate), 1-2 ml intramuscularly and Bivamox® antibiotic (amoxicillin), 2 ml intramuscularly.

The antibiotic and anti-inflammatory medication were administered after surgery and every other day for four days to prevent postoperative infection and inflammation, following the guidelines established by the animal research ethics committees.

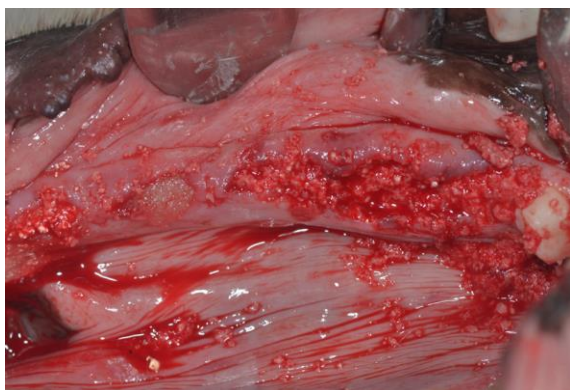


Figure 4: Application of Dentin Grinder in alveolar ridge of premolars and mandibular molars (group A).

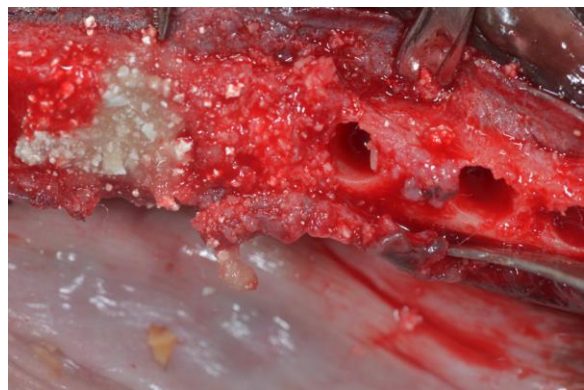

Figure 5. Unfilled premolar zone P2 (Group B Control).

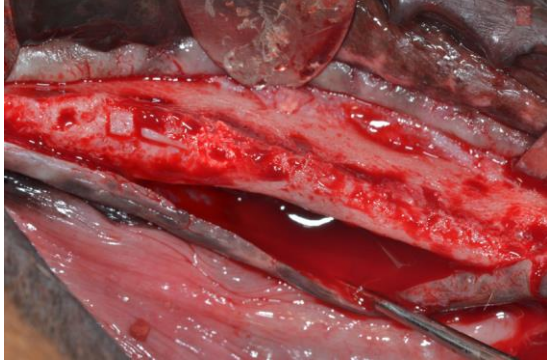


Figure 6: Bone scarring at 90 days

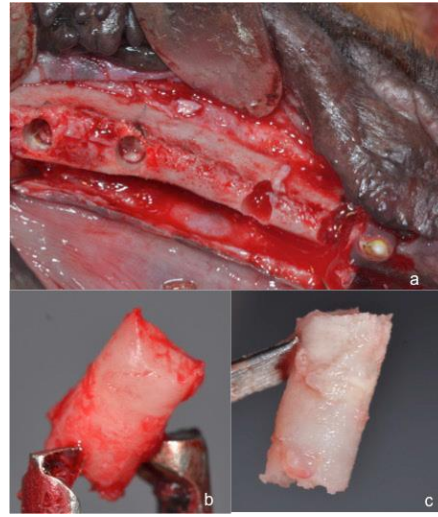


Figure 7: a) biopsy taking by 3 mm trephine, b)Dentin Grinder at 90 days, c) control 90 days

The animals received antibiotics twice a day (Amoxicillin 500 mg Clamoxyl® L.A., Pfizer, Madrid, Spain) and analgesics three times a day (ibuprofen 600 mg, Rimadyl®, Pfizer, Madrid, Spain).

After the surgery the dogs were transferred to each of their cages where they remained under veterinary supervision. During the days following surgery, postoperative care of post-extraction wounds was performed to prevent infection and the general health of the animals was monitored. The animals were fed ad-libitum with a soft diet.

The oral mucosa was disinfected and cleaned with impregnated gauze in a mouthwash based on seawater Sea 4 (Blue Sea Laboratories, Alicante, Spain).

At 60 and 90 days local anesthetic was applied to the vestibular and lingual gums and a crestal incision was made in the area regenerated from the canine to the second molar. A full thickness flap was lifted (Figure 6) and using a 3 mm diameter trephine, biopsies were taken from the control points and regenerated bone at 60 and 90 days on the left and right sides, respectively (Figure 7).

Histology and sample preparation

The obtained bone cylinders were individually preserved in 4% formaldehyde for 15 days. The samples were decalcified for 30 days using TBD-2 (Anatomical Pathology International, Runcorn, Cheshire, United Kingdom). After dehydration and inclusion in paraffin, sections of 8 microns were prepared and stained with picosirius-hematoxylin for Dentin Grinder and hematoxylin for control.

For the histomorphometric analysis, the images were enlarged 20x and digitally evaluated with ten fields per sample (DP12, Olympus, Nagano, Japan). The Microimage 4.0 software (Media Cybernetics, Silver Spring, Maryland, USA) was used for image analysis.

All the analyses were carried out by the same technician who did not know which group (Experimental or Control) each sample belonged to. The area of newly formed bone and connective tissue was evaluated and the percentage of immature bone within the total bone area was determined.

The immature bone was characterized by images of totally disorganized mineralized bone, with high rates of cellularity and large medullary cavities, differentiating it from mature bone, characterized by images showing a predominance of osteons constituted by osseous blades arranged concentrically around the Havers channels.

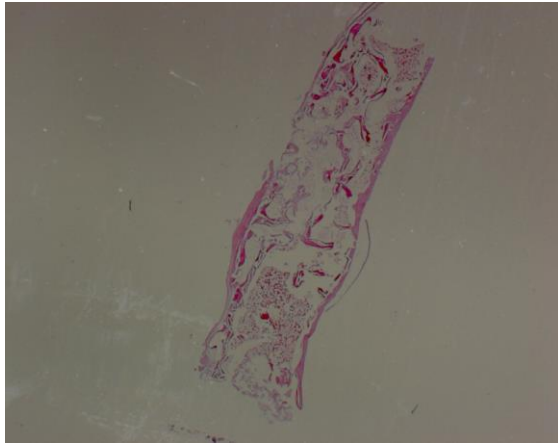


Figure 8. Control Group biopsy showing disorganization of the newly formed bone at 60 days. Hematoxylin-eosin stain x20.



Figure 9. Dentin Grinder biopsy showing an organization of the newly formed and stable bone at 60 days. Picrosirius-hematoxylin stain x20.

Statistical analysis

The values were recorded as mean-standard deviation. For the comparison of the means, a non-parametric Wilcoxon test was applied to related samples, assuming a level of significance of 95% ($P < 0.05$). If the distribution of two paired variables in two related samples is the same, the test takes into account the magnitude of the differences between these two paired variables. Equal means were considered as a null hypothesis, while the existence of significant differences between the media acted as an alternative hypothesis. As significant differences between existing means, the null hypothesis was rejected. All data were expressed as mean averages and standard deviation. The Student's t-test was used to analyze the differences between the variables. Statistical analysis was performed using SPSS 15.0 software (SPSS, Chicago, IL, USA). The significance was established as $p < 0.05$.

“VARIOUS STUDIES
HAVE TRIED TO
DEVELOP BONE
GRAFT MATERIAL TO
REPLACE THE
AUTOGEN BONE

RESULTS

60 DAYS - OPTICAL MICROSCOPY

The Control Group showed large amounts of newly formed bone that covered the bone defect, but this was considered completely immature, represented by images of highly disorganized tissues with high rates of cellularity and large medullary cavities.

The groups treated with dentin particulate were characterized by the presence of newly formed bone that included areas of irregular disposition with high levels of cellularity, but to a lesser extent than the Control Group (Figure 8). The Group of Dentin Grinder treated showed remains of regenerating tooth material, which had been partially resorbed (Figure 9).

Histomorphometric analysis:

The histomorphometry found a total of immature bone of $22.9 \pm 5.91\%$ in defects treated with dentin with significant differences between the control samples ($57.40 \pm 2.30\%$) (Table 1).

At the time of the 60-day measurement, the new bone formation was $81.23 \pm 0.13\%$ in the defects treated with Dentin Grinder, while in the untreated

Histomorphometric values of immature bone formation (mean in mm + standard deviation) at 60 and 90 days of follow-up.

	AMOUNT OF IMMATURE BONE	
	Dentin Grinder (%) Media +/- DS %	Control (%) Media +/- DS
60 Days	22.9 +/- 5.91	57.40 +/- 2.30
90 Days	9.88 +/- 1.42	35.3 +/- 1.23
	*P < 0.05	

Table 1. Mean values ± standard deviation of immature bone at 60 and 90 days of follow-up. Level of significance * P <0.05.

Histomorphometric values of the formation of new bone (mean in mm + standard deviation) at 60 days of healing.

Measurement time – 60 days	Dentin Grinder (%) Media +/- DS %	Control	P - Value
Newly formed bone	81.23 +/- 0.13*	65.89 +/- 0.45 (65.89)	< 0.015*
Connective tissue	18.77 +/- 0.67 (18.77)	34.11 +/- 1.34 (34.11)	<0.092

Table 2. Mean values ± standard deviation of the new bone and connective tissue at 60 days of follow-up. Level of significance * P <0.05.

defects the new bone was 65.89 ± 0.45 % with statistical significance (P <0.05) (Table 2).

90 DAYS - OPTICAL MICROSCOPY

The Control Group showed greater organization Of newly formed bone compared with the first study time of 60 days.

The bone defects were covered, and the images showed concentric sheets that formed osteons while other areas still showed disorganized immature bone in the control group (Figure 10). For the groups treated with Dentin Grinder, the images were characterized by a predominance of mature newly formed bone well organized by osteons, although there were still areas of disorganized bone with high cellularity, in a small proportion of the total bone tissue (Figure 11).

Histomorphometric analysis:

The histomorphometry found a total of immature bone of 9.88 ± 1.42% in defects treated with Dentin Grinder, with significant differences between the control samples (35.3 ± 1.23%) (Table 1). This finding revealed significant differences between the grafted sites compared to the control group. There were also significant differences between this study period and the results obtained at 60 days (Table 1). At the time of the 90-day measurement, the new bone was 92.36 ± 1.7% in defects treated with Dentin Grinder; compared to the control group, the new

Histomorphometric values of the formation of new bone (mean in mm + standard deviation) at 90 days of healing

Measurement time – 90 days	Dentin Grinder (%) Media +/- DS %	Control	P - Value
Newly formed bone	92.36 +/- 1.7	67.88 +/- 1.5	< 0.042+
Connective tissue	7.64	12.22	<0.150

Table 3. Mean values ± standard deviation of the new bone and connective tissue at 90 days of follow-up. Level of significance * P <0.05.

bone was 67.88 ± 1.5% with statistical significance (P <0.05) (Table 3).

observed but with marked crestal reabsorption at 90 days (Figure 15).

Radiovisiography

In Figure 12 we can observe a condensation of bone particles more homogeneous and stable than in bone without filling 90 days after placement in the jaw of Beagle dogs.

In a sagittal section of the alveolus regenerated by Dentin Grinder at 60 and 90 days a marked bone neoformation was observed with predominance of the crestal height of the buccal and lingual tables (Figures 13 and 14). In the Control Group a regeneration of the alveolus was

DISCUSSION

More than 40 years ago, autogenous teeth were routinely transplanted into extraction sites whenever possible. It is evident that the transplanted teeth that are ankylosed in the bone of the jaw underwent replacement resorption by the host bone, for 5-8 years (37). In addition, it is well documented that avulsed teeth that are re-implanted in their sockets undergo integration by the site bone, which is formed directly in the dentin or cement of the root, giving rise to ankylosis (38).

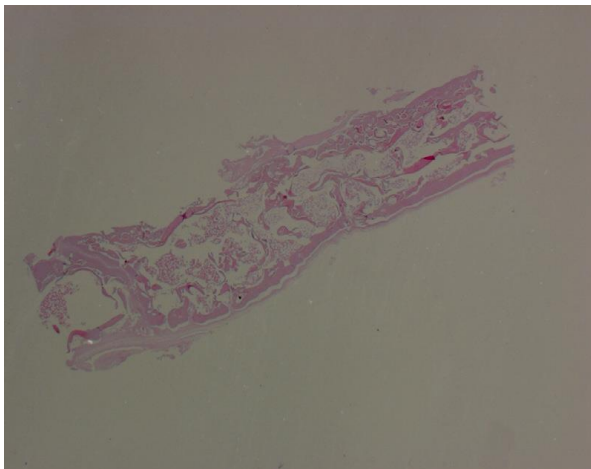


Figure 10. Control Group biopsy showing a large appearance of immature bone, neoformed at 90 days. Hematoxylin-eosin stain x20.

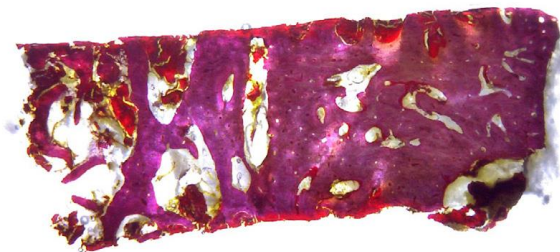


Figure 11. Dentin Grinder biopsy showing a new bone, with mature osteons and new bone around the particles at 90 days. Picrosirius-hematoxylin stain x20.

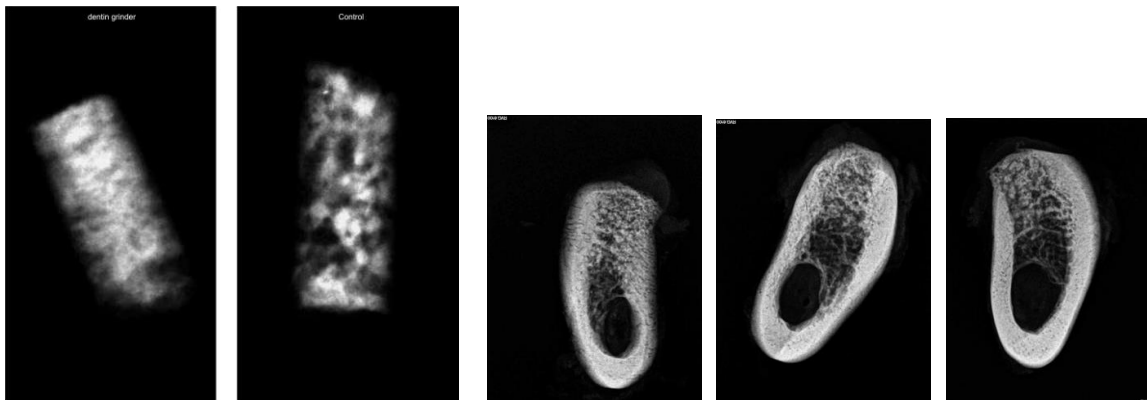


Figure 12: Radiovisiography of group a and b.

Figures 13-15. (13) Sagittal radiovision of group A at 60 days with great bone neoformation and maintenance of bone corticals. (14) Sagittal radiovision of group A at 90 days with great bone neoformation and poor crestal resorption. (15) Sagittal radiovision of group B at 90 days with crestal reabsorption in stage of bone maturation.

Since the Urist study, where bone generation was examined after applying demineralized tooth to different parts of the bone, the ability of the tooth to generate bone has not been investigated sufficiently. However, his results have clearly showed that tooth can generate bone. This could be ideal for achieving osteoconduction, osteoinduction and osseointegration, and due to its autologous nature, it does not trigger a foreign body reaction ensuring rapid healing (39-41). An ankylosed root is continuously resorbed over time and replaced by bone, eventually resorbing the entire root, while the alveolar process is conserved during this period and subsequently. In a recent review, Malmgren (42) emphasized that ankylosed teeth that are treated by discoloration, the alveolar crest is maintained in the buccal / palatal direction, while the vertical height is maintained even higher (43).

Our results reveal a similar interaction between the mineralized dentin and the osteogenic cells that bind and produce the mineralized bone matrix directly on the dentin particulate.

Bone graft material derived from the tooth with absence of antigenicity improves bone remodeling capabilities. Among a variety of bone graft materials available choosing the right one is a challenge. While the choice of graft material

should be dictated by the extent of the defects and the purpose of the procedure, the bone graft derived from teeth can be considered as an option given its autogenous origin and favorable clinical and histological results when the extraction of the tooth is necessary.

A tooth bank in Korea provides a service that prepares the autogenic demineralized dentine matrix as a block or granular type, delaying the grafting procedure from several hours to several days and, therefore, needs an additional surgical session (44, Four. Five). Although demineralized dentin exhibits matrix-derived growth and differentiating factors for effective osteogenesis, newly formed bone and residual demineralized dentin are weak to support the anchoring of the implant. On the contrary, our Smart Dentin Grinder protocol allows the preparation of dentin as bacteria-free particulate from freshly extracted autologous teeth, ready to be used immediately as autogenous during the same surgical session.

**“THE MINERALIZED
DENTIN IS INTEGRATED
WITH THE NEWLY
FORMED BONE
CREATING A SOLID SITE
FOR IMPLANTS**

In addition, despite the inductive properties, the mineralized dentin is integrated with the newly formed bone, creating a solid site for the anchoring of dental implants. In fact, there are clinician who describe clinical studies that indicate that the insertion and loading of the

implant can be done in mandibles lower and upper jaws 2-3 months in a crushed tooth mesh (46, 47).

Since mineralized dentine is remodeled very slowly compared to cortical bone or most biomaterials, the aesthetic and structural integrity of the alveolar ridge and the mucoperiosteum is maintained for years (48, 49).

In fact, many research studies have been carried out to develop bone graft material in order to replace autogenous bone. In particular, Kim et al. They introduced a bone graft material using the extracted tooth as a new bone graft material to overcome the disadvantages of the allograft, xenograft and synthetic graft.

The patient's tooth is a bone graft material with all the advantages of autogenous bone due to its very similar components to bones and is very useful in clinical situations. It also addresses the rejection of patients to the sources of allograft and xenograft, providing excellent biocompatibility without causing an immune response, foreign material reaction or infection. In addition, it has osteoinduction, osteoconduction and progressive substitution capabilities, and it can be manufactured in various sizes and shapes (11-13).

Furthermore, the use of the patient's own tooth is not illegal if the patient agrees to process and use their own teeth. Unless it is contaminated by an infectious lesion, a tooth does not cause problems, even when the root tip is left in the alveolar bone. There are also surgeries in which the root tip is left intentionally to preserve the alveolar bone (37, 38).

In our study, the bone regeneration at 90 days with the Dentin Grinder was superior to the control and even more, preserving the bone crests in height and width evaluated in the dogs. In addition, Kim et al. reported that 90% of the organic components of the tooth are type I collagen, which is very important in bone calcification (38-50). The teeth and the jaw have a high level of affinity, with similar chemical structure and composition. Therefore, we and others [45] propose that non-functional extracted teeth or periodontally involved teeth should not be discarded any longer. The extracted teeth can be converted into an autogenous dentine ready to be ground within 15 minutes of extraction and can be grafted into alveolar ridge post-extraction.

“CHOOSING THE OPTIMAL BONE GRAFT FROM ALL AVAILABLE OPTIONS, IS A CHALLENGE

CONCLUSIONS

We consider that autogenous dentine can be viewed as a standard for the preservation of the alveolar ridge by the characteristics similar to autologous bone, for bone augmentation of the maxillary sinus and for small and large bone defects. The particulate of autogenous mineralized dentin that is obtained after the extractions could be considered as a good biomaterial for the preservation of the bone. Currently, this graft material can be used with autologous bone as a graft without losing the capacity for bone regeneration.

BIBLIOGRAPHY

1. Horowitz R, Holtzclaw D, Rosen PS. A review on alveolar ridge preservation following tooth extraction. *J Evid Based Dent Pract.* 2012; 12: 149-160.
2. Nanci, A. *Ten Cate's Oral Histology, 7th ed.* Elsevier Inc. 2008, 202-211.
3. Min B. M *Oral Biochemistry.* Daehan Narae Pub Co. Seoul. 2007; 22-26.
4. Bhaskar SN. *Orban's Oral histology and embryology.* 9th edition. Mosby Co. USA. (1980)
5. Kim YK, Kim SG, Byeon JH, Lee HJ, Um IU, Lim SC. Development of a novel bone grafting material using autogenous teeth. *Oral Surg Oral Med Oral Pathol Oral Radiol Endod.* 2010; 109: 496-503.
6. Murata M, Maki F, Sato D, Shibata T, & Arisue M. Bone augmentation by onlay implant using recombinant human BMP-2 and collagen on adult rat skull without periosteum. *Clin Oral Impl Res.* 2000; 11, 289-295.
7. Murata M, Arisue M, Sato D, Sasaki T, Shibata T, & Kuboki Y. Bone induction in subcutaneous tissue in rats by a newly developed DNA-coated atelocollagen and bone morphogenetic protein. *Br J Oral Maxillofac Surg.* 2002; 40, 131-135.
8. Akazawa T, Murata M, Sasaki T, Tazaki J, Kobayashi M, Kanno T, Matsushima K, & Arisue M. Biodegradation and bioabsorption innovation of the functionally graded cattle-bone-originated apatite with blood compatibility. *J Biomed Mater Res.* 2006; 76A, 1, 44-51.
9. Murata M, Akazawa T, Tazaki J, Ito K, Sasaki T, Yamamoto M, Tabata Y, & Arisue M. Blood permeability of a novel ceramic scaffold for bone morphogenetic protein-2. *J Biomed Mater Res.* 2007; 81B, 2, 469-475.

10. Akazawa T, Murata M, Hino J, Nakamura K, Tazaki J, Kikuchi M, & Arisue M. Materials design and application of demineralized dentin/apatite composite granules derived from human teeth. *Archives of Bioceramics Research*. 2007; 7, 25-28.
11. Kim SG, Kim HK, Lim SC. Combined implantation of particulate dentin, plaster of Paris, and a bone xenograft (Bio-Oss) for bone regeneration in rats. *J Craniomaxillofac Surg*. 2001; 29: 282-8.
12. Kim SG, Chung CH, Kim YK, Park JC, Lim SC. The use of particulate dentin-plaster of Paris combination with/without platelet-rich plasma in the treatment of bone defects around implants. *Int J Oral Maxillofac Implants* 2002; 17: 86-94.
13. Kim SY, Kim SG, Lim SC, Bae CS. Effects on bone formation in ovariectomized rats after implantation of tooth ash and plaster of Paris mixture. *J Oral Maxillofac Surg*. 2004;62:852-7.
14. Choi DK, Kim SG, Lim SC. The effect of particulate dentin-plaster of Paris combination with/without fibrin glue in the treatment of bone defects around implants. *Hosp Dent* 2007; 19: 121-6.
15. Park SS, Kim SG, Lim SC, Ong JL. Osteogenic activity of the mixture of chitosan and particulate dentin. *J Biomed Materials Res* 2008; 87A: 618-23.
16. Kim SG. Bone grafting using particulate dentin. *Key Eng Mater* 2007; 342-343: 29-32.
17. Ku HR, Jang HS, Kim SG, Jeong MJ, Park JC, Kim HJ, et al. Guided tissue regeneration of the mixture of human toothash and plaster of Paris in dogs. *Key Eng Mater*. 2007; 330-332: 1327-30.
18. Hwang YJ, Kim SG, Yoon JH, Lim SC. Effect of the bone regeneration of the mixture of human, bovine, pig, rabbit, or dog tooth-ash and the plaster of Paris in rats. *J Korean Maxillofac Plast Reconstr Surg*. 2004; 26: 155-61.
19. Na TH, Kim SG, Yoon JH, Lim SC. Effect of the bone regeneration of the mixture of human or bovine tooth-ash and the plaster of Paris in rats. *J Korean Maxillofac Plast Reconstr Surg* 2004; 26: 334-40.
20. Kim YK, Yeo HH, Ryu CH, Lee HB, Byun UR, Cho JE. An experimental study on the tissue reaction of toothash implanted in mandible body of the mature dog. *J Korean Maxillofac Plast Reconstr Surg*. 1993; 15: 129-36.
21. Kim YK, Yeo HH, Cho JO. The experimental study of implantation combined with toothash and plaster of paris in the rats: comparison according to the mixing ratio. *J Korean Maxillofac Plast Reconstr Surg*. 1996; 18: 26-32.
22. Kim YK, Yeo HH, Yang IS, Seo JH, Cho JO. Implantation of toothash combined with plaster of Paris: experimental study. *J Korean Maxillofac Plast Reconstr Surg*. 1994; 16: 122-9.
23. Kim SG, Yeo HH, Kim YK. The clinical study of implantation of toothash combined with plaster of Paris: long-term followup study. *J Korean Maxillofac Plast Reconstr Surg*. 1996; 18: 771-7.
24. Kim YK, Yeo HH, Park IS, Cho JO. The experimental study on the healing process after the inlay implantation of toothash-plaster mixture block. *J Korean Maxillofac Plast Reconstr Surg*. 1996; 18: 253-60.
25. Kim YK, Yeo HH, Park IS, Cho JO. The experimental study on the healing process after the inlay implantation of toothash-plaster mixture block. *J Korean Maxillofac Plast Reconstr Surg*. 1996; 18: 253-60.
26. Kim YK. The experimental study of the implantation of toothash and plaster of Paris and guided tissue regeneration using Lyodura. *J Korean Assoc Oral Maxillofac Surg*. 1996; 22: 297-306.
27. Kim YK, Yeo HH. Transmitted electronic microscopic study about the tissue reaction after the implantation of toothash. *J Korean Assoc Oral Maxillofac Surg*. 1997; 23: 283-9. 19.
28. Kim YK, Kim SG, Lee JH. Cytotoxicity and hypersensitivity test of toothash. *J Korean Maxillofac Plast Reconstr Surg*. 2001; 23: 391-5. 20.
29. Kim YK, Ko YM. Biomechanical study of the calvarial defects after implantation of the toothash and plaster in the rat. *J Korean Maxillofac Plast Reconstr Surg*. 1997; 19: 45-54. 21.
30. Kim YK. The development of new biomaterial for restoration of hard tissue defects. *J Kor Dent Assoc*. 1998; 36: 289-95. 22.
31. Kim SG, Choi YO, Kim YK. Histologic evaluation of peri-implant defects with a particulate dentin-plaster of Paris combination and bioresorbable membrane barriers: a preliminary study. *Hosp Dent (Tokyo)*. 2004; 16: 15-8. 23.
32. Kim YK, Kim SG, Lee JG, Lee MH, Cho JO. An experimental study on the healing process after the implantation of various bone substitutes in the rats. *J Korean Assoc Oral Maxillofac Surg*. 2001; 27: 15-24.
33. Kim SG, Kim YK. Restorative and grafting material for hard tissue defect and fabrication method of the same using animal teeth. Patent No. 20040202984.
34. Kim YK. Toothplaster and manufacturing method thereof. Patent application no. 1019980008980. Korea Intellectual Property Rights Information Service.
35. Murata M. Autogenous demineralized dentin matrix for maxillary sinus augmentation in human: The first clinical report. *J Dent Res* 82: B243, 2003.
36. Pang K-M, Um I-W, Kim Y-K, Woo J-M, Kim S-M, Lee J-H. Autogenous demineralized dentin matrix from extracted tooth for the augmentation of alveolar bone defect: a prospective randomized clinical trial in comparison with anorganic bovine bone. *Clin. Oral Impl. Res.* 2016, 1-7.
37. Sperling I, Itzkowitz D, Kaufman A, Binderman I. A new treatment of heterotransplanted teeth to prevent progression of root resorption. *Endod Dent Traumatol*. 1986; 2: 117-120.
38. Andersson L, Bodin I, Sörensen S. Progression of root resorption following replantation of human teeth after extended extraoral storage. *Endod Dent Traumatol*. 1989; 5: 38-47.
39. Urist MR. Bone: Formation by autoinduction. *Science*, 150. 1965; 893-899.
40. Urist MR, Iwata H, Ceccotti PL, Dorfman RL, Boyd SD, McDowell RM, & Chien C. Bone morphogenesis in implants of insoluble bone gelatin. *Proc Nat Acad Sci USA*. 1973; 70, 3511-3515.
41. Urist MR, Mizutani H, Conover MA, Lietze A, & Finerman GA. Dentin, bone, and osteosarcoma tissue bone morphogenetic proteins. *Prog Clin Biol Res*. 1982; 101, 61-81.
42. Malmgren B. Ridge preservation/decoronation. *J Endod*. 2013; 39: S67-72.
43. Park CH1, Abramson ZR, Taba M Jr, Jin Q, Chang J et al. Three-dimensional micro-computed tomographic imaging of alveolar bone in experimental bone loss or repair. *J Periodontol*. 2007; 78: 273-281.
44. Young-Kyun Kim, Junho Lee, In-Woong Um, Kyung-Wook Kim, Masaru Murata, Toshiyuki Akazawa, Masaharu Mitsugi. Tooth-derived bone graft material. *J Korean Assoc Oral Maxillofac Surg* 2013; 39: 103-111.
45. Kim YK. Bone graft material using teeth. *Journal of the Korean Association of Oral and Maxillofacial Surgeons*. 2012; 38: 134-138.
46. Yeomans JD, Urist MR. Bone induction by decalcified dentine implanted into oral, osseous and muscle tissues. *Arch Oral Biol*. 1967; 12: 999-1008.
47. Huggins C, Wiseman S, Reddi AH. Transformation of fibroblasts by allogeneic and xenogeneic transplants of demineralized tooth and bone. *J Exp Med*. 1970; 132: 1250-1258.
48. Kim YK, Kim SG2, Yun PY1, Yeo IS3, Jin SC4, et al. Autogenous teeth used for bone grafting: a comparison with traditional grafting materials. *Oral Surg Oral Med Oral Pathol Oral Radiol*. 2014; 117: e39-45.
49. Andersson L. Dentin xenografts to experimental bone defects in rabbit tibia are ankylosed and undergo osseous replacement. *Dent Traumatol*. 2010; 26: 398-402.
50. Binderman I, Hallel G, Nardy C, Yaffe A, Sapoznikov L. A Novel Procedure to Process Extracted Teeth for Immediate Grafting of Autogenous Dentin. *J Interdiscipl Med Dent Sci*. 2014; 2: 154. doi: 10.4172/jimds.1000154.